Paris Brain Institute
ICM

MR Imaging in atypical parkinsonian syndromes

Stéphane Lehericy MD, PhD

Session: Atypical Parkinsonian syndromes

ERN-RND Winter School 2023 - NEUROIMAGING

March 24, 2023

ASSISTANCE PUBLIQUE HÔPITAUX DE PARIS | cnrs | Inserm | SORBONNE UNIVERSITÉ

Learning objectives

- Identify the main imaging clues pointing to a specific group of parkinsonism.
- Describe indication and interpretation of imaging investigations for atypical parkinsonism.

Overview

Parkinson's disease and atypical parkinsonism

- PD, MSA, PSP

Imaging biomarkers in the substantia nigra

Imaging biomarkers in atypical Parkinsonism

- Progressive supranuclear palsy
- Multiple system atrophy, cerebellar type
- Multiple system atrophy, parkinsonian type
- Prodromal parkinsonism, REM sleep behavior disorders

Artificial intelligence and automated categorization

Overview and diagnostic algorithm

arkinson's disease and atypical parkinsonism

Parkinsonism

arkinson's disease

typical Parkinsonism

uopathies

- **Progressive supranuclear palsy**
  - Richardson syndrome
  - Variants
- **Corticobasal syndrome**

ynucleinopathies

- **Multiple system atrophy**
  - Parkinsonian
  - Cerebellar
- **Dementia with Lewy body**

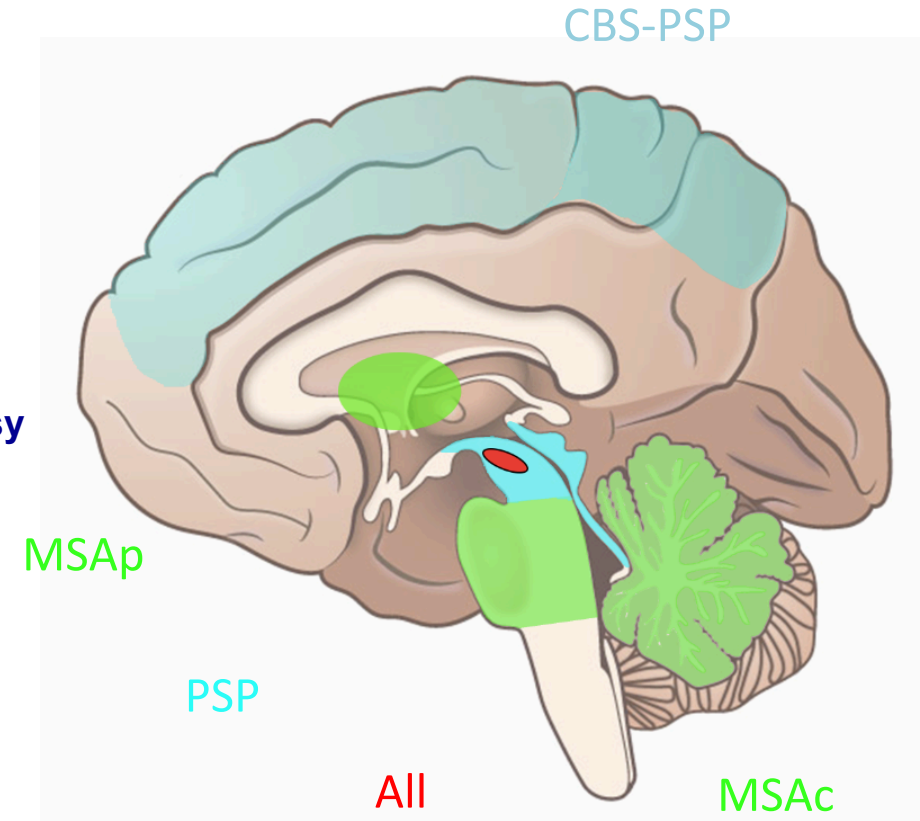

- **Red flags**

- Bilateral symmetric parkinsonism
- Poor response to dopaminergic medica
- ⇒ **PSP**
- Rapid progression of gait impairment
- Recurring falls due to impaired balance 3 years of symptom onset.
- Eye movement dysfunction
- ⇒ **MSA**
- Severe autonomic failure in the first 5 y
- Cerebellar signs

…

Postuma et al. Mov Disord 2015

Imaging

New criteria for MSA include MRI
Wenning et al. *Mov Disord* 2022

Imaging biomarkers in the substantia nigra

Neuromelanin imaging

Iron imaging and the dorsal nigral hyperintensity sign

MRI biomarkers in the substantia nigra

Qualitative biomarkers

- **Quantitative biomarkers**

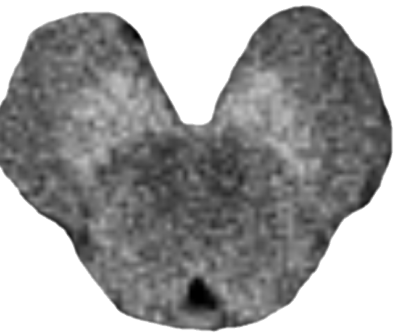

Neuromelanin imaging

Melanized neurons

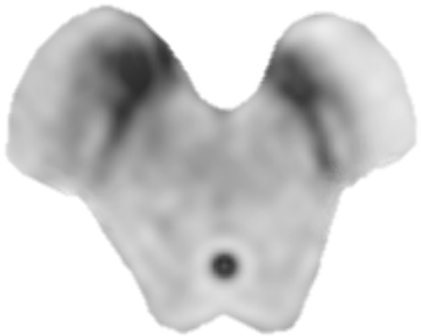

SWI at 3T
(T2* at 7T)

Dorsal nigral hyperintensity



R2* / QSM

Brain iron



Fractional anisotropy
Free water

Water diffusion

FA ↘ ↗ **FW**

Chougar et al. *Font Neurol* 2021, Peralta *Mov Disord Clin practice* 2022 (reviews)

) Substantia nigra **neuromelanin MRI** in parkinsonism

Dopaminergic neurons of the SNc contain a **pigment** neuromelanin

Neuromelanin is associated with dopamine metabolism (Sulzer NPJ PD 2018)

Neuromelanin is **paramagnetic** => Hyperintense on 3T high-res T1-w (Sazaki Neuroreport 2006)

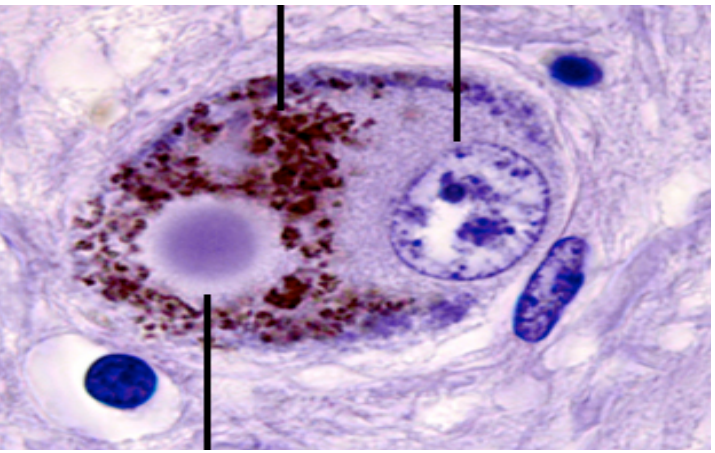

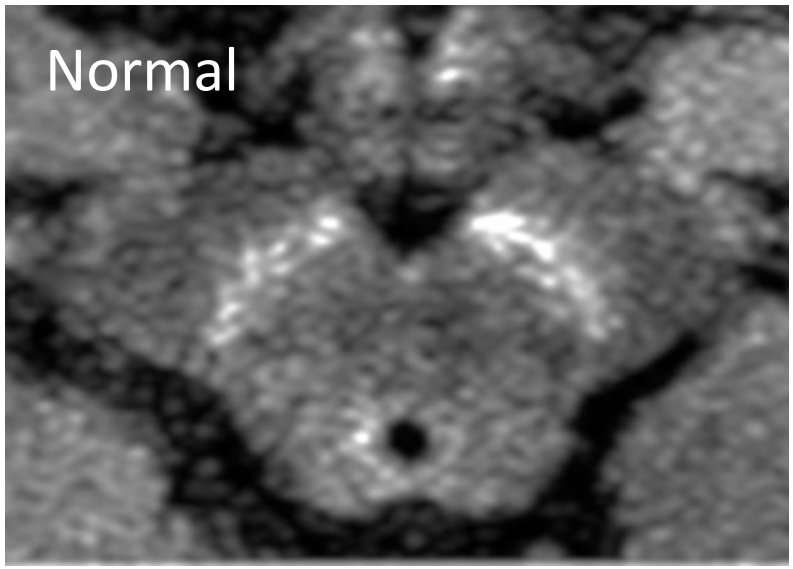

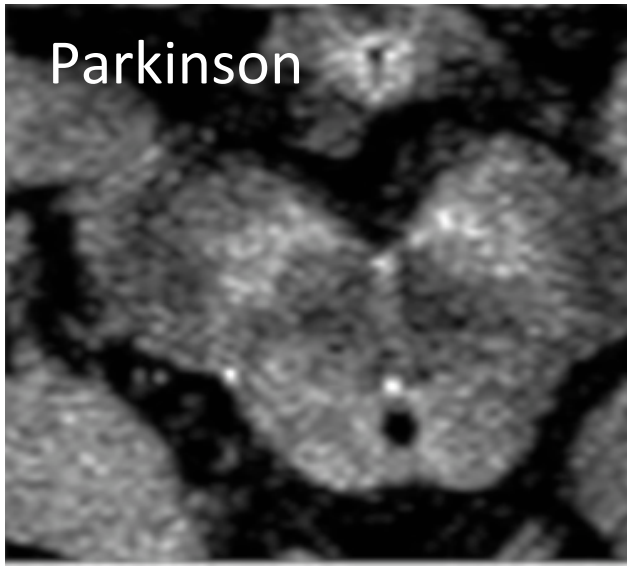

Chougar et al. Front Neurol 2020 (review)
Peralta et al. MDCP 2021 (review)

Schwarz et al. *Mov Dis* 2011 (Nottingham)

) Substantia nigra **neuromelanin MRI** in parkinsonism

Reduced neuromelanin signal => sign of neurodegenerative parkinsonism

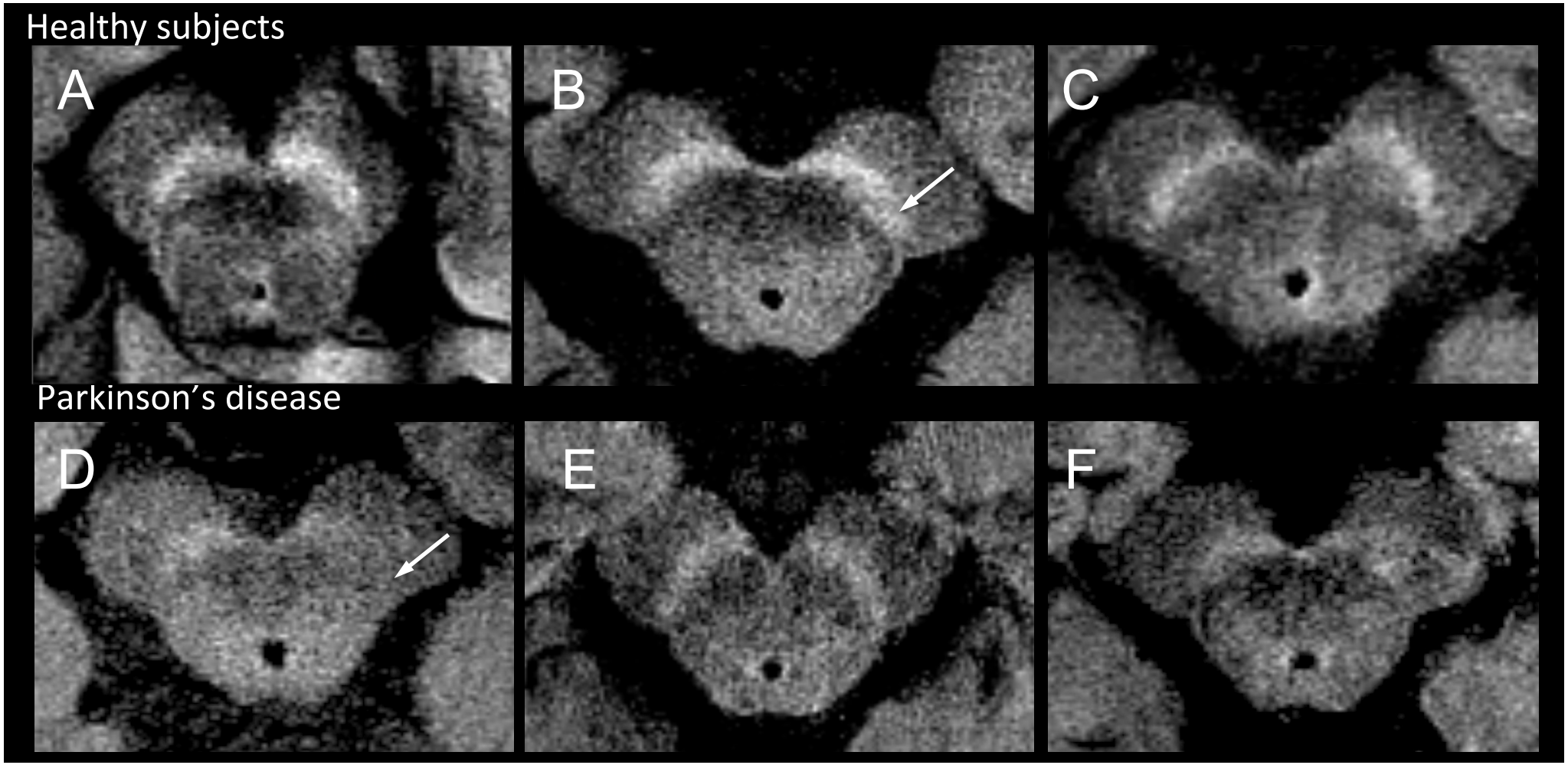

) Substantia nigra **neuromelanin MRI** in parkinsonism

A marker of parkinsonism

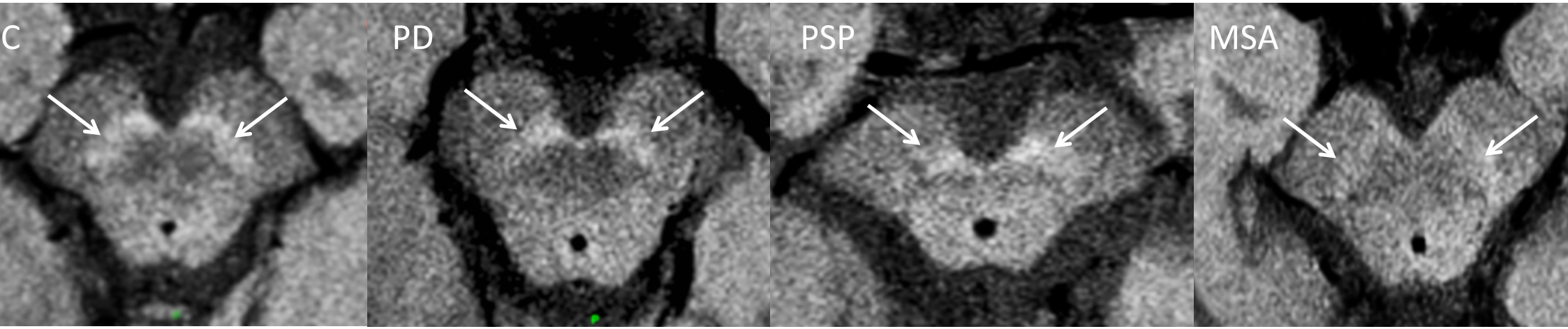

Visual reading : Parkinsonism vs Control

Sens./Spe. 83-90% accuracy 86%

Chougar et al. *Mov Disord* 2022

Peralta et al. *Mov Disord Clin Practice* 2021 (review)

Normal in

- Vascular and drug-induced parkinsonis
- Essential tremor

Reimão et al. *Mov Disord* 2015

) Substantia nigra **neuromelanin MRI** in parkinsonism

NM-MRI is a longitudinal biomarker

Biondetti *Brain 2020, Gaurav Mov Disord 2021*

HC	Early PD	Advanced PD
Disease duration	3.7 years	11.8 years

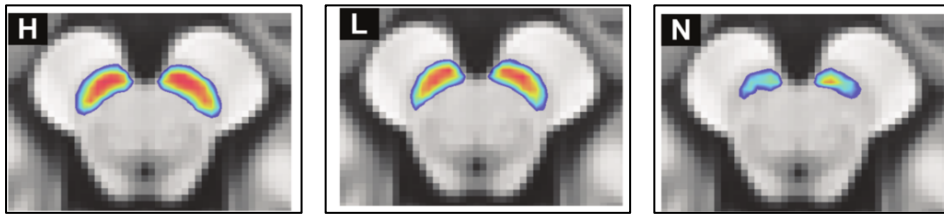

Volume changes	-12.8%	-65.4%

Nigral NM-MRI changes begin 5-6 years before disease onset

Xing et al. *Mov Disord 2022*

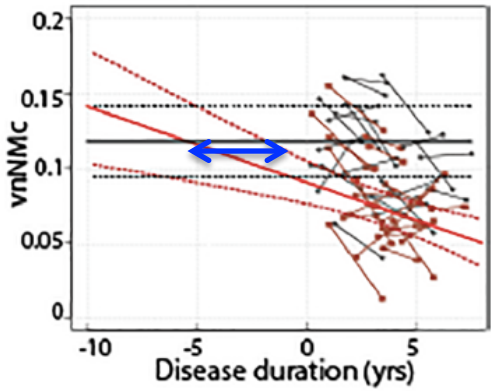

Nigral NM-MRI changes correlate with motor severity and disease duration

Biondetti et al. *Brain 2020*

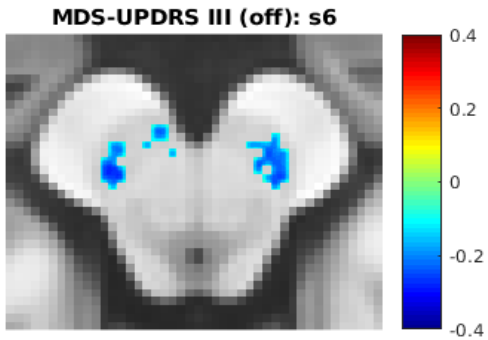

Biondetti et al. *Brain 2021*

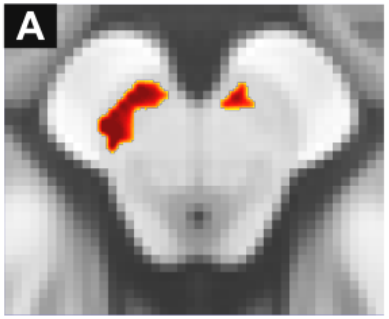

DA
putam
NM i

) The **dorsal nigral hyperintensity sign** in parkinsonism

The DNH sign – swallow tail sign (MRI) / nigrosome 1 (histology)

rosome-1

ier *Brain* 1999

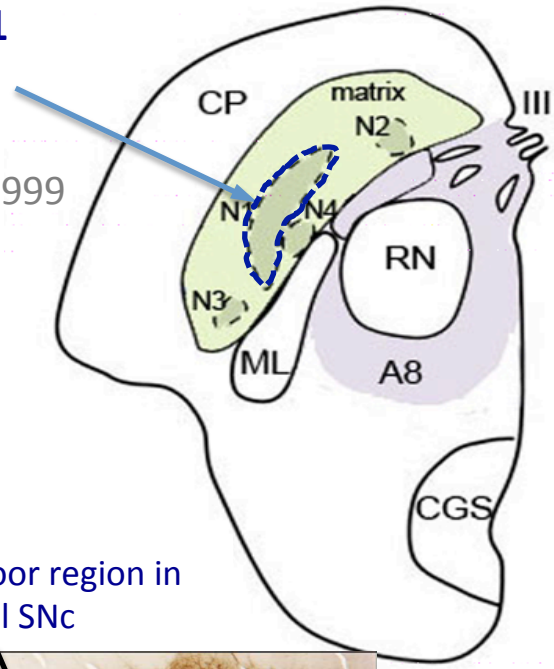

Calbindin-poor region in
dorso-lateral SNc

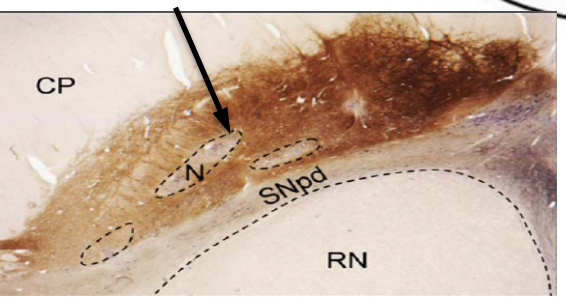

Loss of T2* hyperintense area of the dorsolateral part of SNc

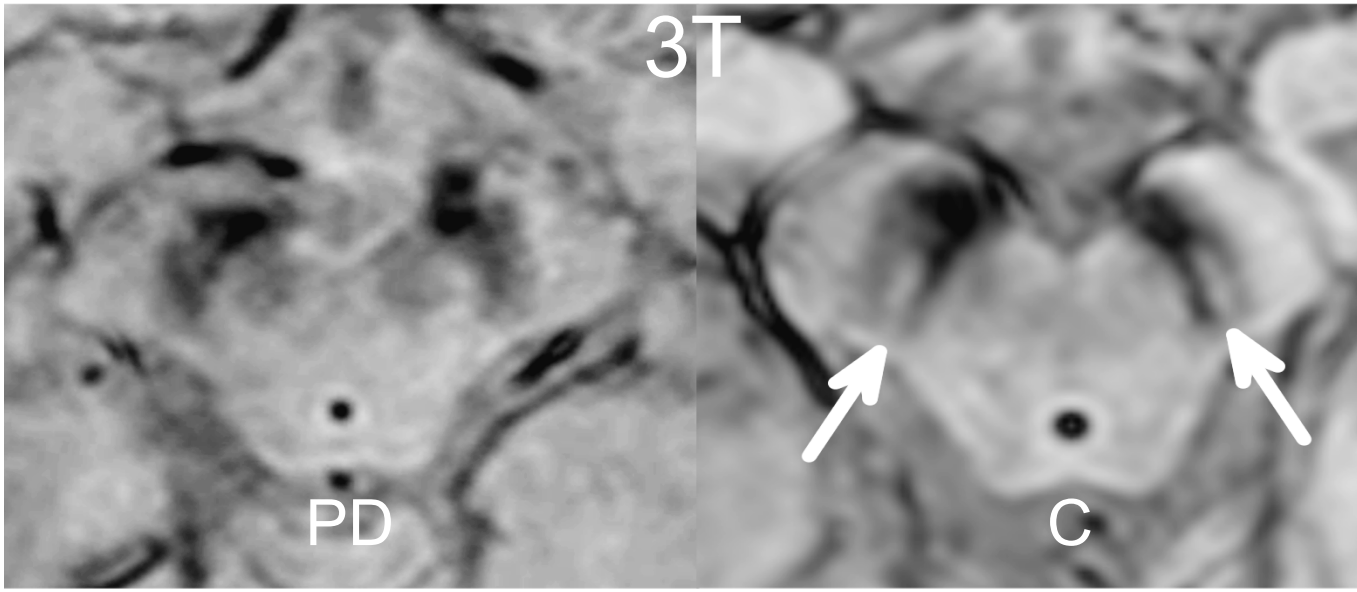

Schwarz *Plos One* 2014 (Nottingham)

Normal in:

- Vascular and drug-induced parkinsonism
- Essential tremor

) The **dorsal nigral hyperintensity sign** in parkinsonism

Loss of DNH / swallow tail sign => sign of neurodegenerative parkinsonism

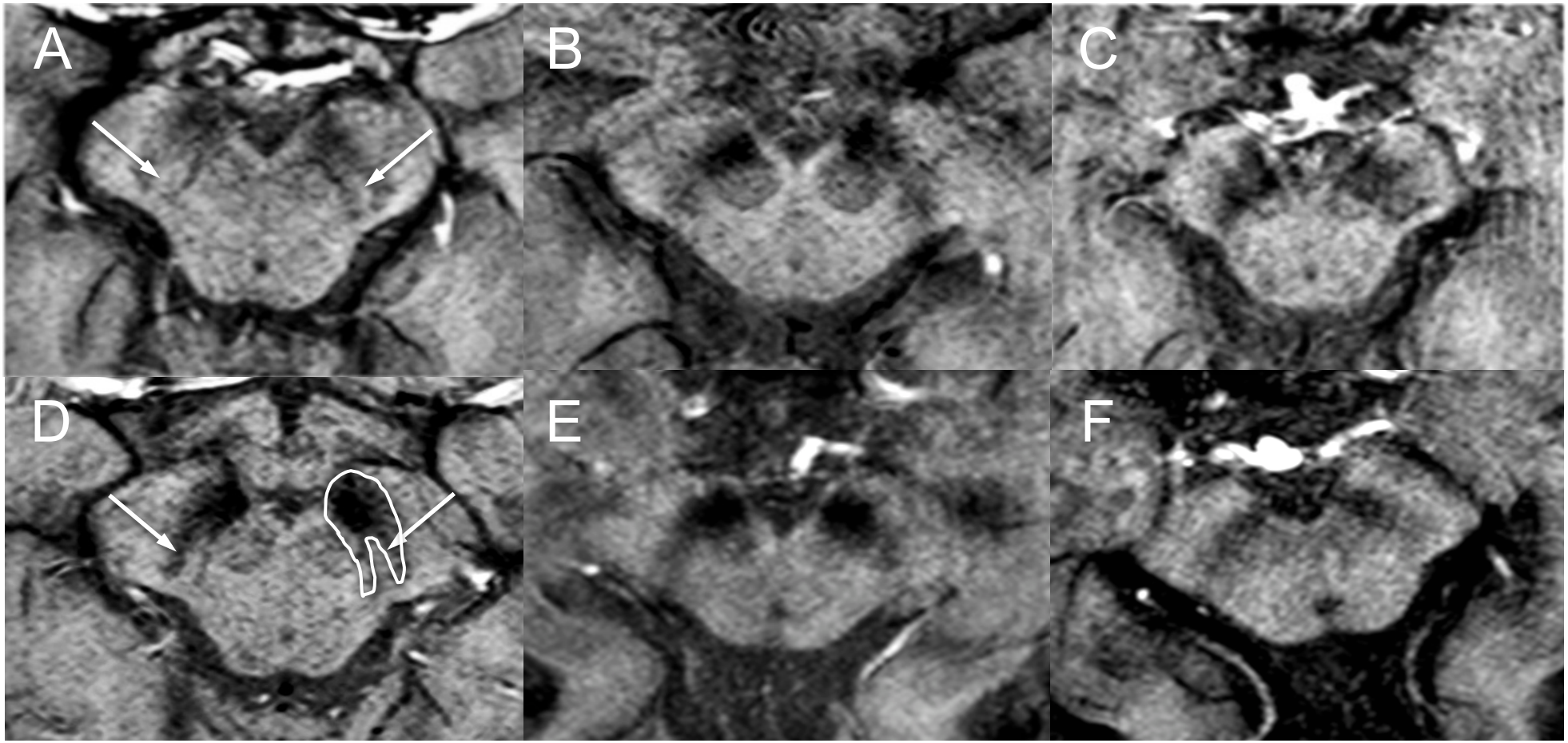

- Roughly corresponds to the Nigrosome 1 in histology
- **PD: Sensitivity** & **Specificity** >90%

Schwarz Plos One 2014, Mahlknecht *Mov Dis* 2
(meta-analysis), Brammerloh *Radiology* 2022

) The **dorsal nigral hyperintensity sign** in parkinsonism

The DNH sign – swallow tail sign (MRI) / nigrosome 1 (histology)

A marker of Parkinsonism

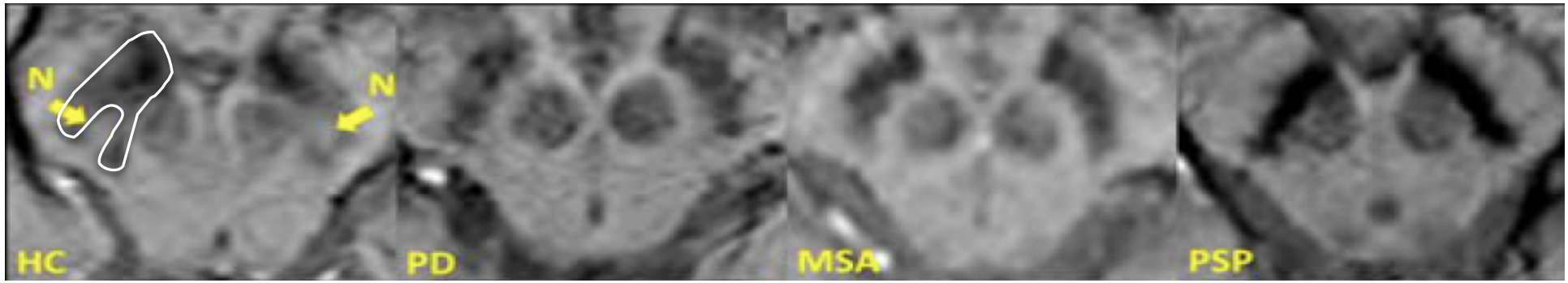

Reiter *Mov Dis* 2015 (Innsbruck, Austria)

PD/MSA/PSP vs Control

Sens./Spe. >90-95%

Mahlknecht *Mov Dis* 2017 (meta-analysis)

swallow tail sign

Schwarz et al. Plos one 2014

Imaging biomarkers in Progressive Supranuclear Palsy

Midbrain atrophy

Progressive supranuclear palsy

A specific pattern of brainstem atrophy

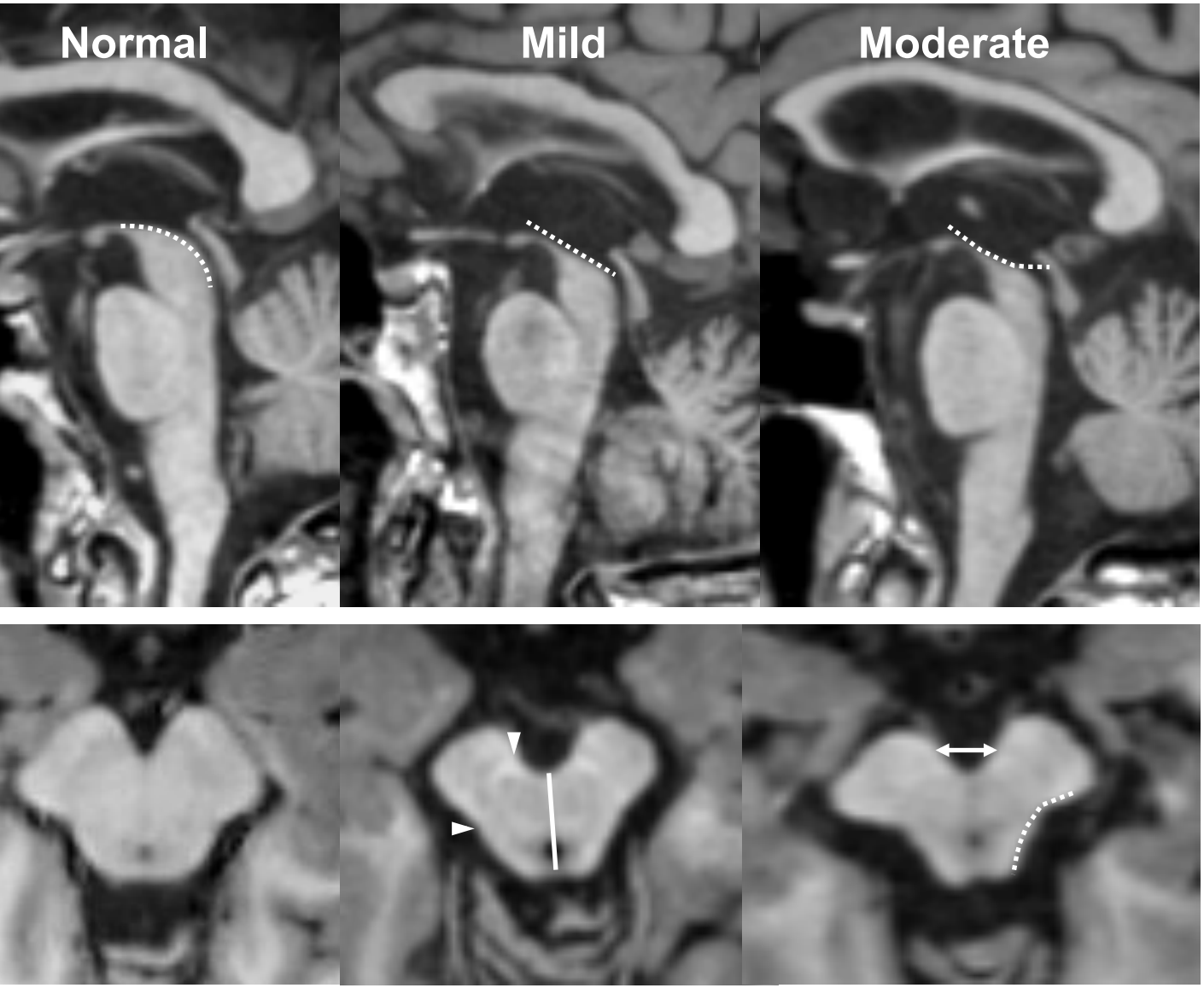

<u>Sagittal plane</u>: Hummingbird sign

- Flattening or concave aspect of the upper border of the midbrain

Kat et al. *J Neurol Sci* 2003 (Japan)

<u>Axial plane</u>: morning glory flower

- Reduced AP diameter
- Enlargement of interpeduncular cistern
- Thinning of cerebral peduncle
- Concave lateral margin of tegmentum

Adachi et al. Reson Med Sci. 2004 *(Japan)*

Progressive supranuclear palsy

Brainstem measurements in clinical practice

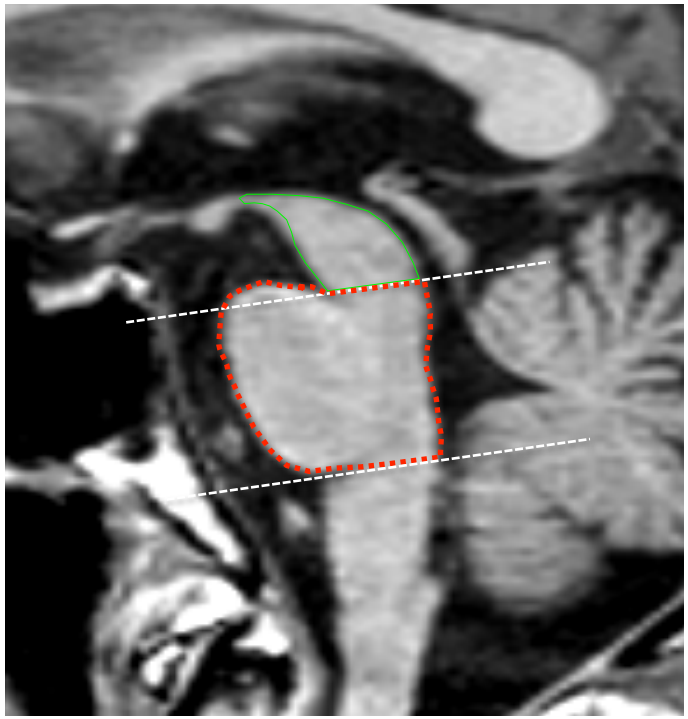

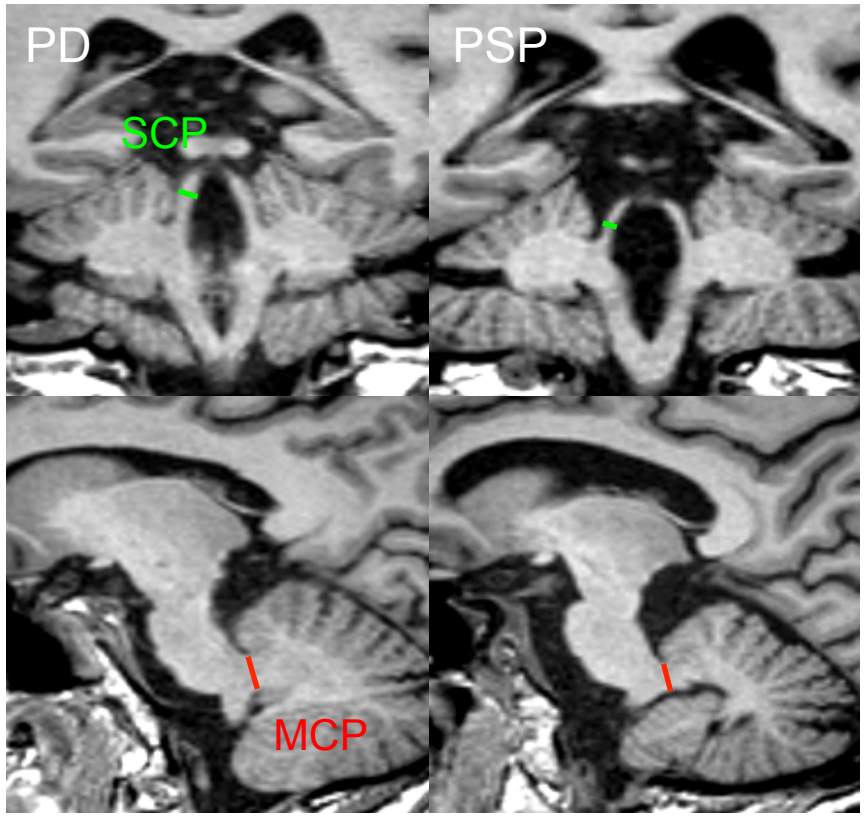

- **Surface** of midbrain
- Midbrain / pons surface ratio

MR Parkinsonian Index (MRPI)

$$\frac{P \times MCP}{M \times SCP}$$

Moller *Mov Disord* 2017 (meta-analysis), Whitwell *Mov Disord* 2017 and Chougar Curr Opin Neurol 2021 (reviews)

Quattrone et al. *Radiology* 2008 (Italy)

Brainstem measurements: diagnostic cut-offs in clinical practice

PSP-Richardson	vs. PD/HC	vs. MSA
Midbrain area (mm^2)	< 120	< 114
Midbrain/Pons	< 0.20	< 0.18
MRPI	> 13.6	> 12.9

⇒ Sensitivity/specificity high for PSP-RS typically > 90% (less for variants)

⇒ Supportive of the clinical diagnosis at the individual level, probably early markers

Moller *Mov Disord* 2017 (meta-analysis), Whitwell *Mov Disord* 2017, Chougar *Curr Opin Neurol* 2021, Peralta MDCP 2021 (reviews)
Illán-Gala, *JAMA Netw* 2022

Progressive supranuclear palsy variants

PSP variants

Höglinger et al. *Mov Disord* 2017

Classical form — **Richardson syndrome**

- Parkinsonism
- Vertical supranuclear gaze palsy
- Postural instability, gait freezing and falls < 3 years
- Non-fluent/agrammatic aphasia

Variants

Subcortical signs

PSP-P	PSP with predominant parkinsonism
PSP-PAGF	PSP with pure akinesia with gait freezing

Cortical signs

PSP-F	PSP with predominant frontal presentation
PSP-SL	PSP with a predominant speech/language disorder
PSP-CBS	PSP with predominant corticobasal syndrome

Less midbrain atrophy in PSP variants

- **PSP variants** have midbrain atrophy although less severe than in PSP-RS
  - MRPI 71 - 88.5%
  - Sens/Spe 83% / 85%

Quattrone A et al. *Parkinsonism Relat Disord 2018, Picillo M et al. JNNP 2020, Grijalva Mov Disord 2021*

Imaging biomarkers in Multiple System Atrophy cerebellar type

Brainstem, cerebellum and cerebellar peduncles

Multiple system atrophy cerebellar form

MSAc: Atrophy in the pons, cerebellum and cerebellar peduncles

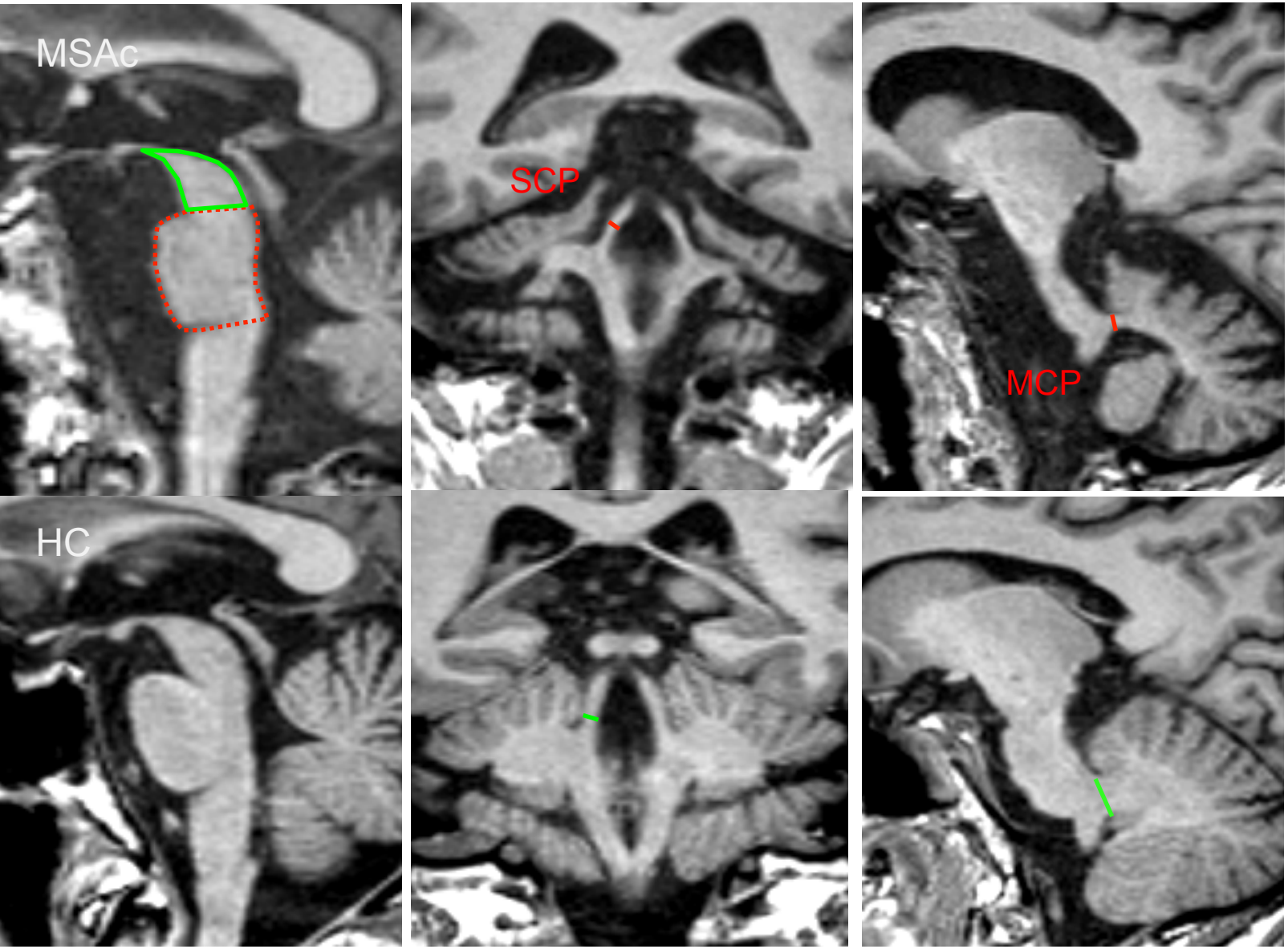

MSAc **MRPI** = 4-8

MSAp mostly normal

MSAc: Atrophy and signal changes in the pons, cerebellar peduncles and cerebellum

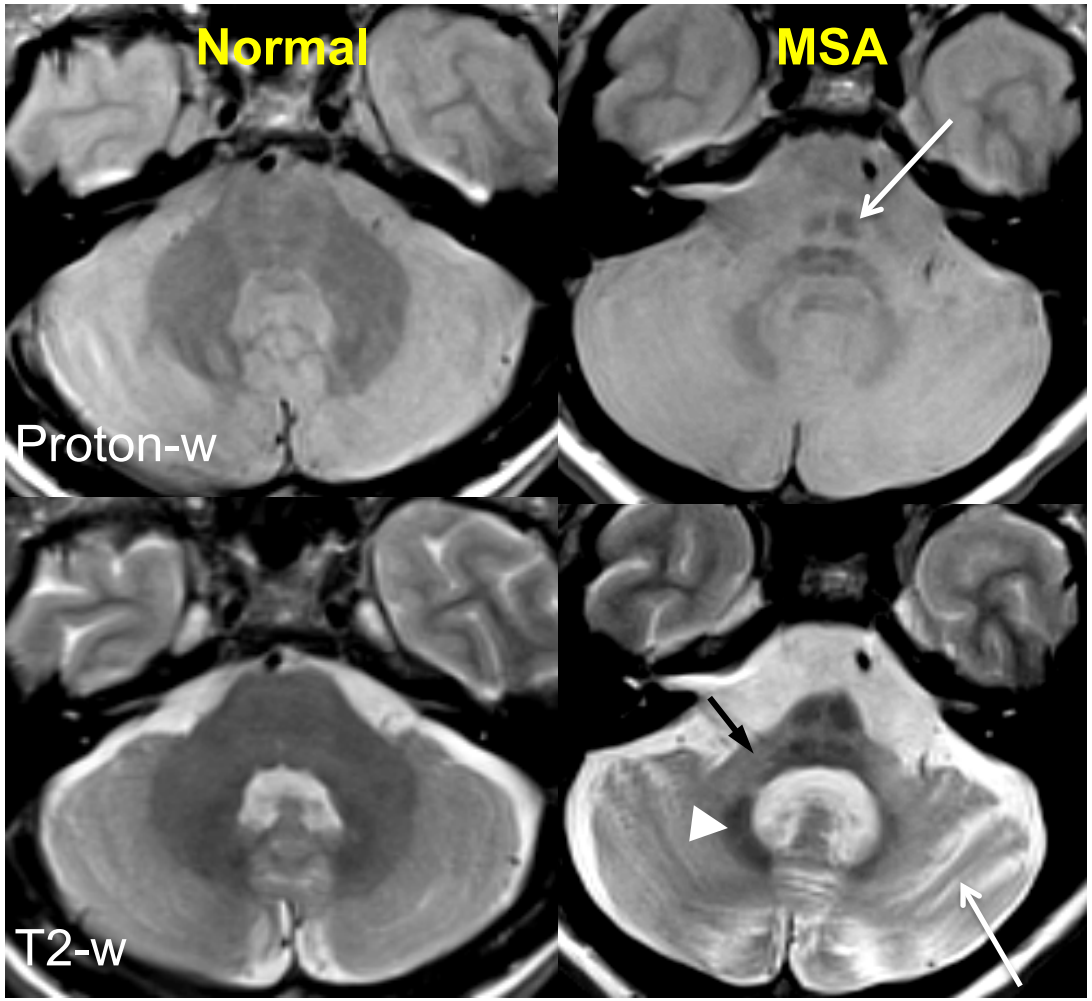

Specificity > 95%

- **Atrophy of the pons and cerebellar peduncles**
- **Cerebellar atrophy**
- **Cross bun sign** = proton density ++
- **PD/T2 hypersignal** of the middle cerebellar peduncles
- **Hyposignal of dentate nucleus**

Carre et al. J Neurol 2020
Kim et al. Sci Rep 2019

Imaging biomarkers in Multiple System Atrophy parkinsonian type

Putamen

Multiple system atrophy (synucleinopathy)

MSAp: Atrophy and signal changes in the posterior putamen

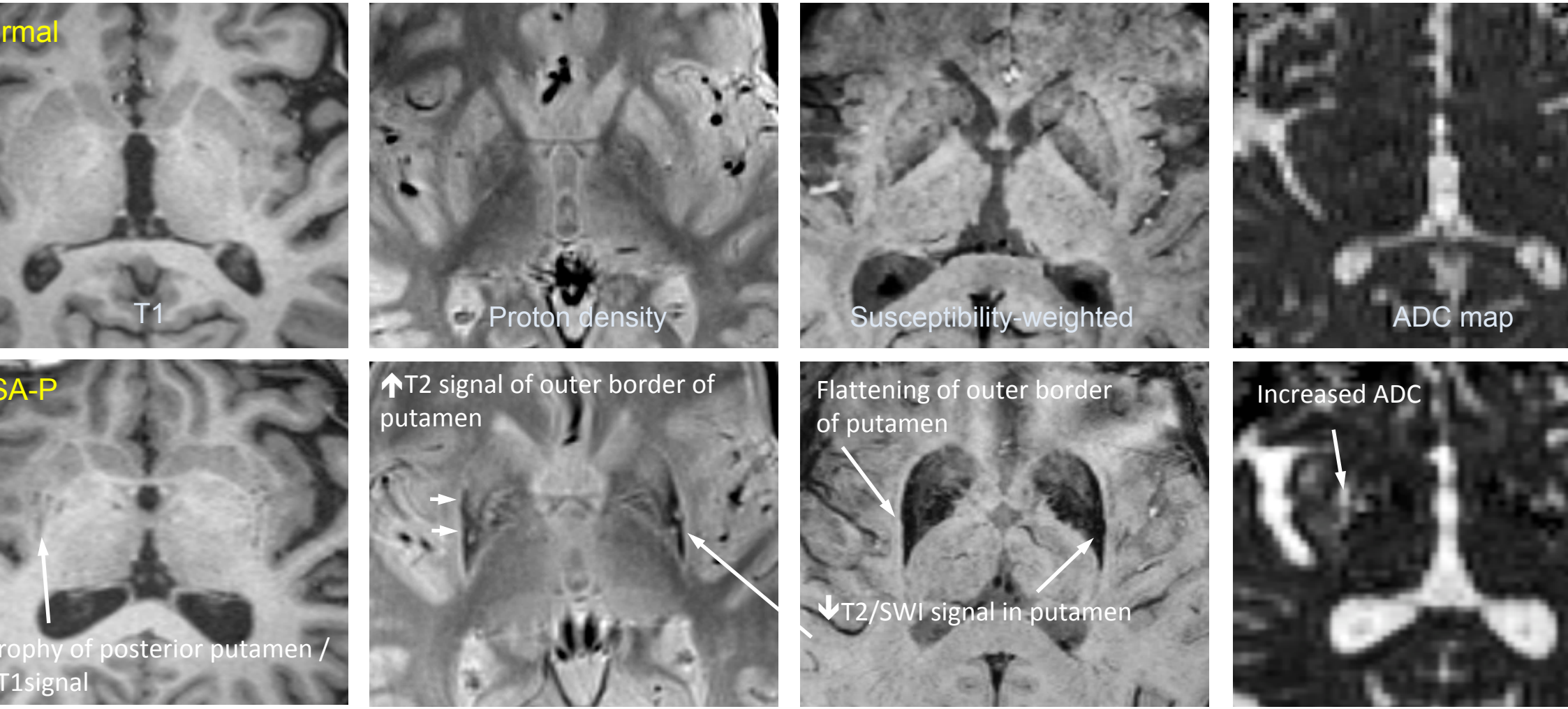

High specificity 87 – 100%

Chougar et al. *Curr Opin Neurol* 2021, Peralta *Mov Disord* 2

MRI signs of MSAp and MSAc are associated in approximately half of patients

- MSAp and MSAc signs are frequently associated (46-61%)

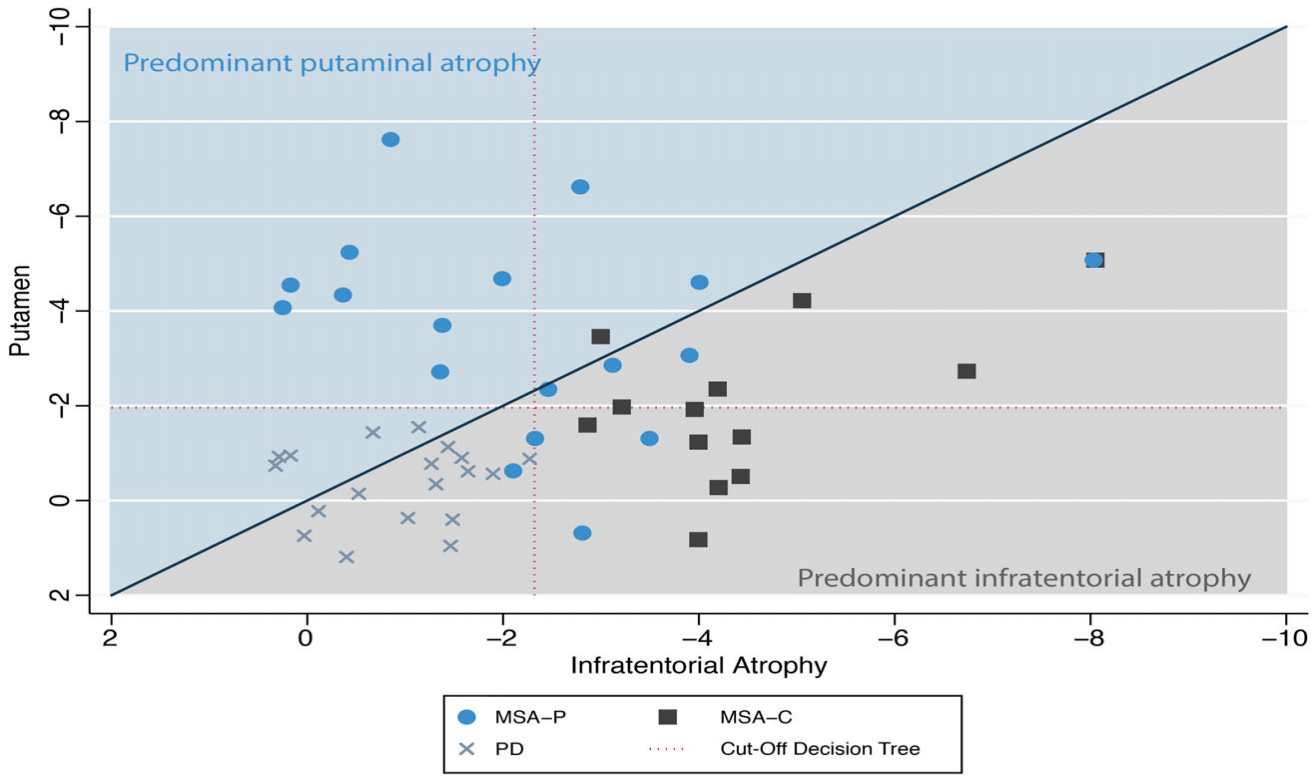

Krismer et al. *Mov Disord* 2019

Imaging biomarkers in prodromal parkinsonism

Isolated rapid eye movement sleep behavior disorders

Prodromal Parkinsonism

Isolated REM sleep behavior disorders (iRBD) is considered a prodromal phase of parkinsonism

- Syndrome of **abnormal behavior** and increased muscle tone
- During **rapid eye movement (REM) sleep**

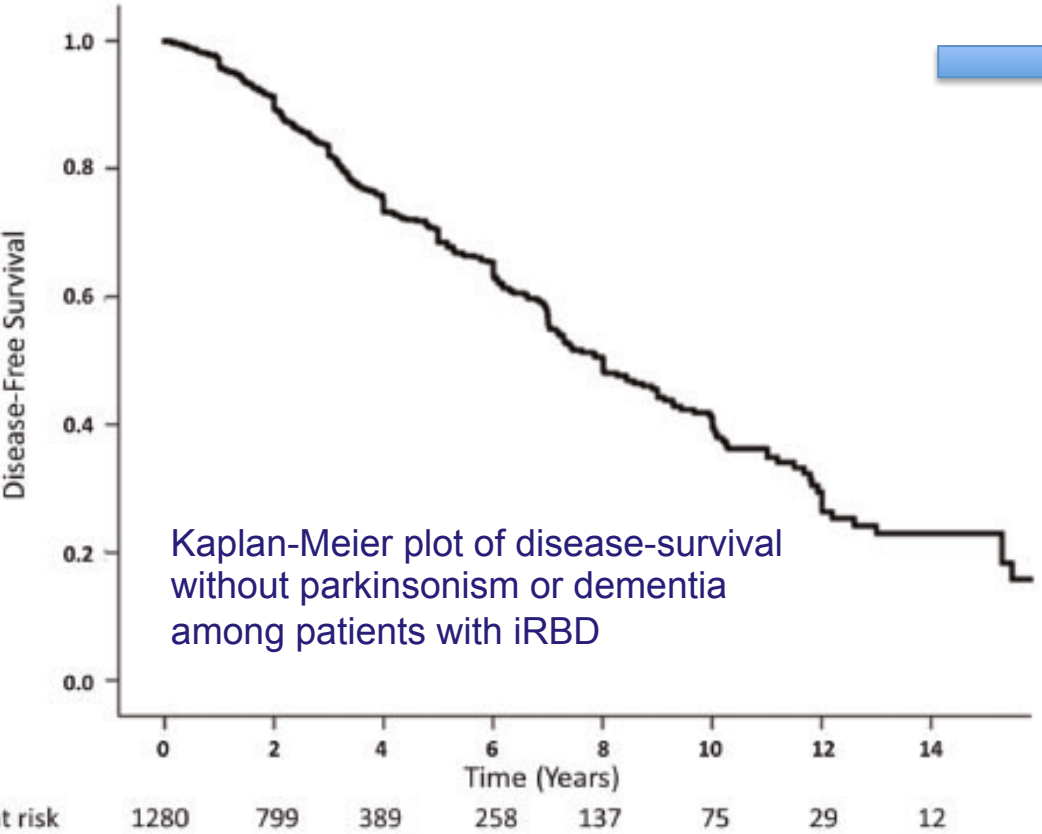

Kaplan-Meier plot of disease-survival without parkinsonism or dementia among patients with iRBD

- Parkinson's disease
- Multiple system atrophy
- Dementia with Lewy body

Iranzo et al. *Lancet Neurol* 2011

Postuma et al. *Brain* 2019

Substantia nigra biomarkers in isolated RBD

ss of dorsal nigral hyperintensity sign (2/3 of patients)

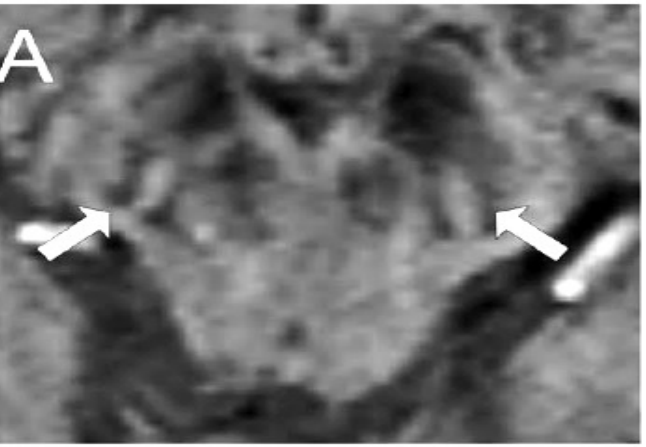

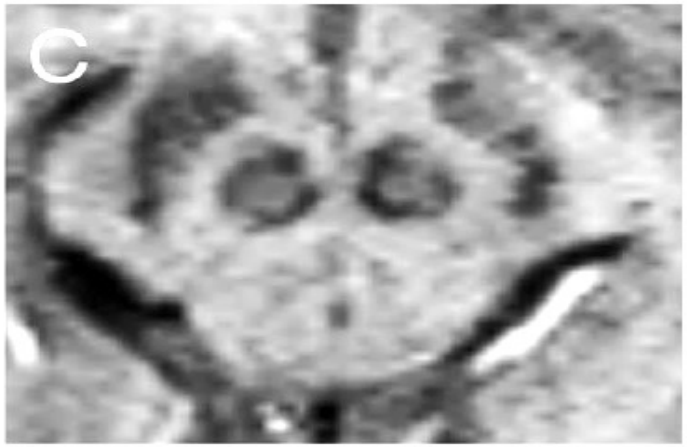

De Marzi et al. *Ann Neurol* 2016
(Insbruck, Austria)

duced neuromelanin signal

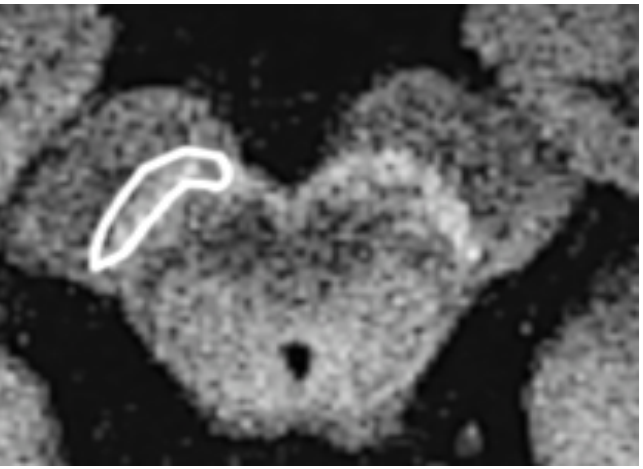

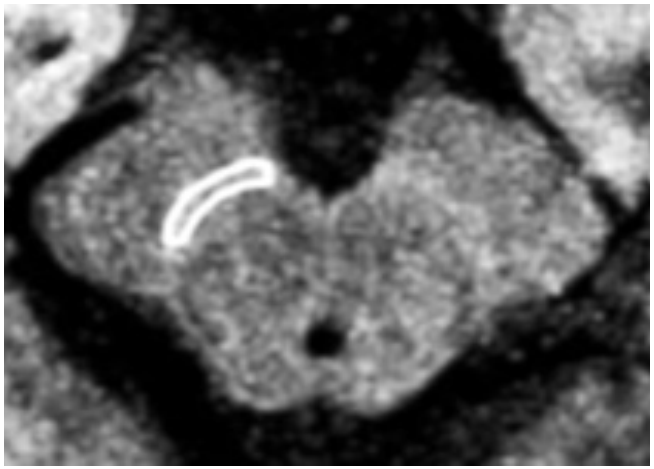

Gaurav et al. *Mov Disord* 2022
(ICM)

The locus coeruleus/subcoeruleus complex in prodromal Parkinsonism

Neuromelanin signal is reduced in the locus coeruleus / subcoeruleus complex in iRBD

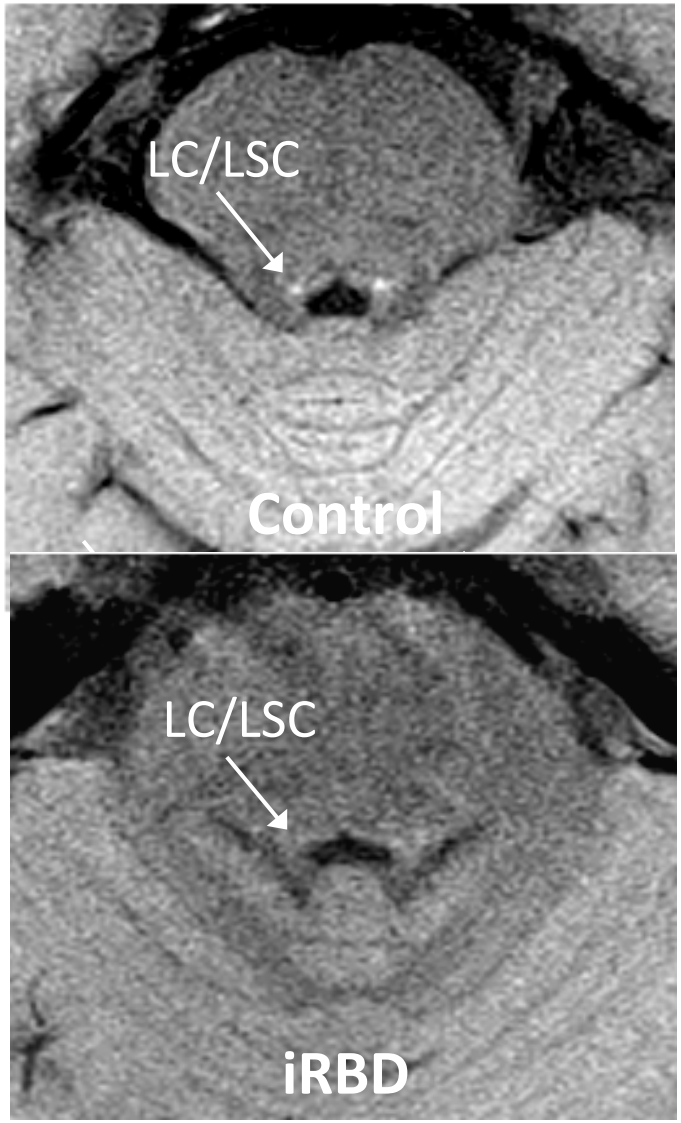

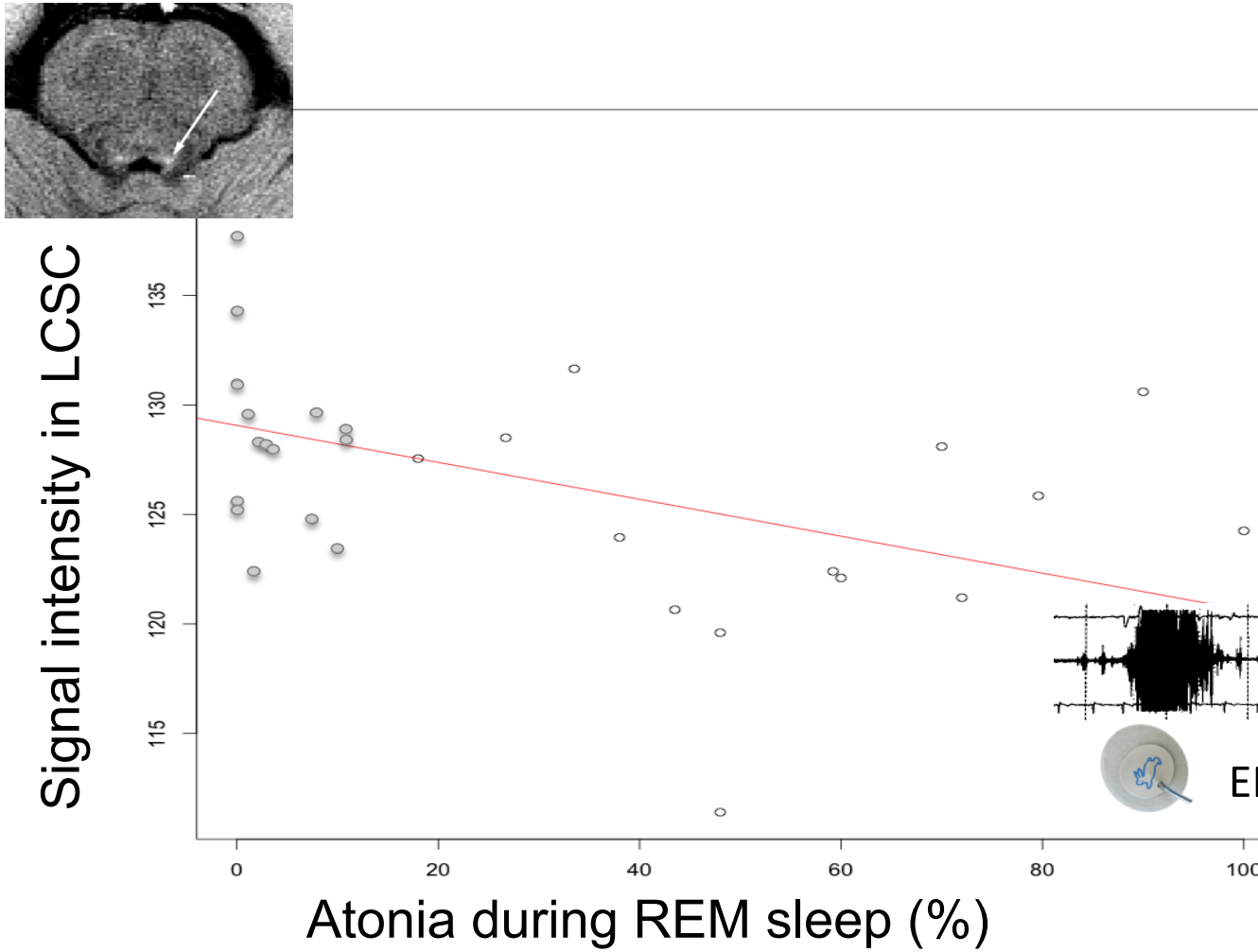

Ehrminger et al. *Brain* 2016

The locus coeruleus in Parkinsonism

Reduced neuromelanin signal in PD with RBD, MSA and PSP

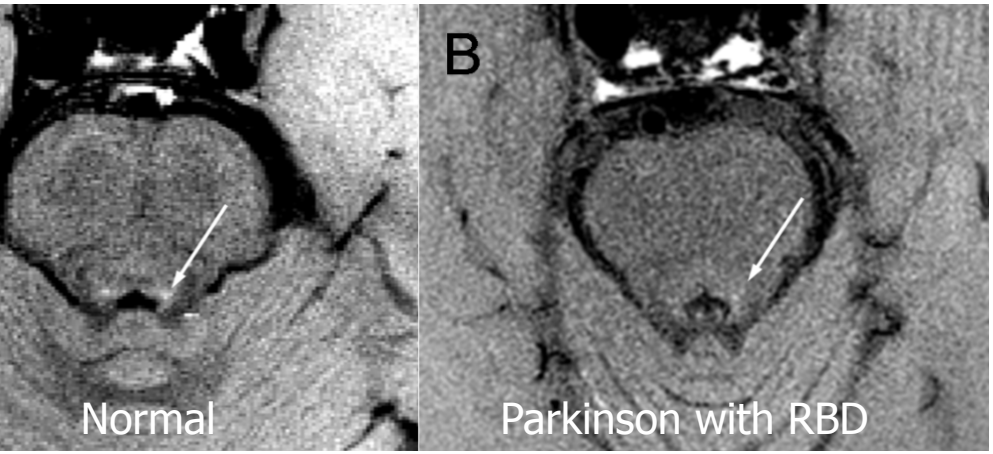

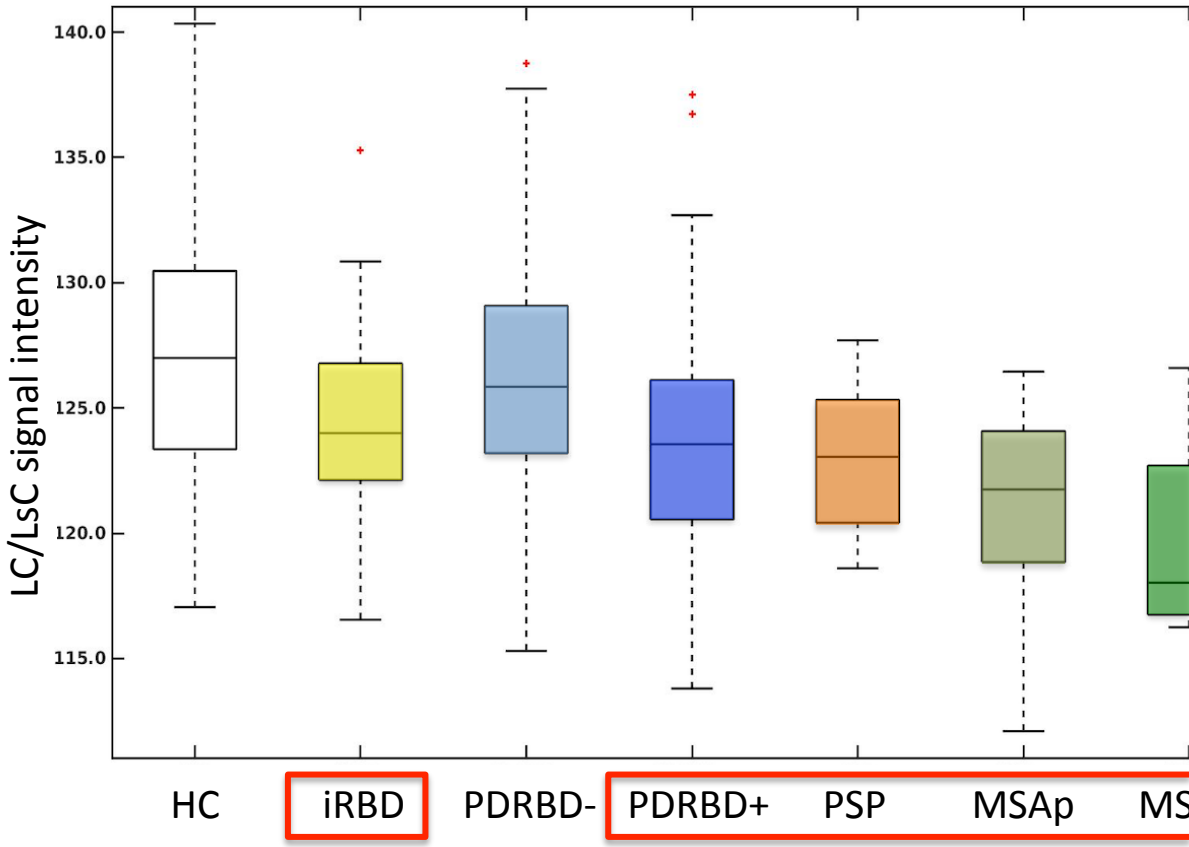

Garcia-Lorenzo et al. *Brain* 2013

Nobileau et al. *Mov Disord* 2023

Quantitative biomarkers and automated categorization

Quantitative biomarkers

Classification algorithms

Automated categorization using machine learning

Support vector machine using quantitative volumetry in 464 participants

Huppertz et al. *Mov Disord* 2016

Support vector machine using free water in 1002 participants

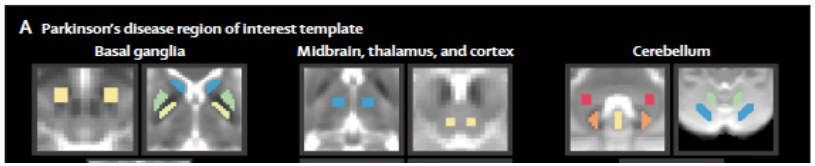

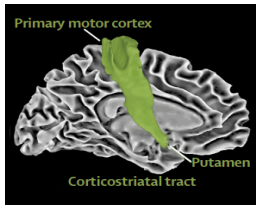

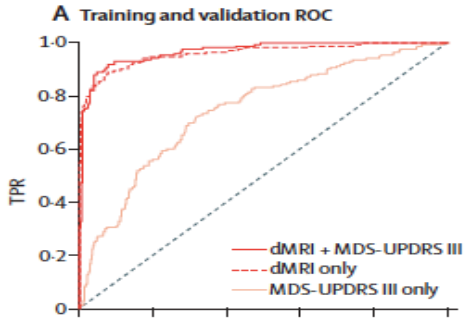

Archer et al. *Lancet Dig Health* 2019

Supervised categorization using clinical multimodal MRI in 322 participants

Chougar et al. *Mov Disord* 2021

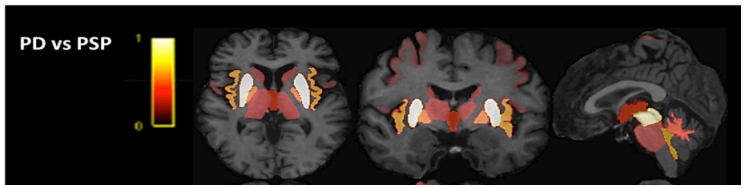

- Good Classification PD, PSP and MSA
- AUC > 0.90
- Sensitivity & specificity 80% to 95%

Overview and diagnostic algorithm

Overview and diagnostic algorithm

eralta, Strafella, van Eimeren, Ceravolo, Seppi, Kaasinen, Arena, Lehericy, On behalf of IPMDS-Neuroimaging Study Group. MDCP 2021

Suggested MRI protocol

- **MRI protocol in clinical practice in Parkinsonism**

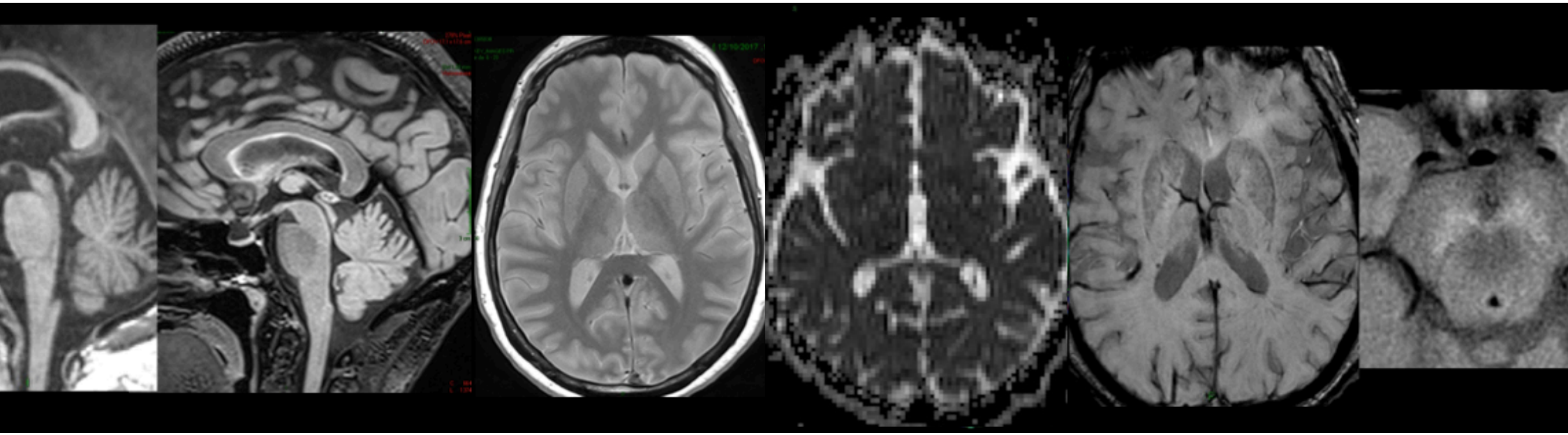

3D T1 **3D FLAIR** **T2 - PD** **DWI** **SWI-DNH** **T1 neuromela**

15-20 min 7 min

Acquisition time

uggested MRI algorithm in clinical practice

MRI to exclude non degenerative parkinsonism and search for red flags

earch for signs of degenerative Parkinsonism

es

SWI: Swallow tail sign
NM MRI: Reduced neuromelanin signal

o

Consider other diagnostic possibilities: Essential tremor, drug-induced…

Search for red flags

MSAp:
- **3DT1:** Putaminal atrophy and signal changes
- **DWI:** Increased diffusivity in putamen

MSAc:
- **Proton density:** Hot cross bun sign
- **3DT1:** cerebellar, pons and MCP atrophy, MRPI < 5, MCP<8mm
- **FLAIR:** Increased signal in MCP

PSP:
- **3DT1**: Hummingbird sign, SCP atrophy, MRPI >13.6, M/P<0.21

eralta, Strafella, van Eimeren, Ceravolo, Seppi, Kaasinen, Arena, Lehericy, On behalf of IPMDS-Neuroimaging Study Group. *Mov Dis Clin Practice* 202

Paris Brai Institut

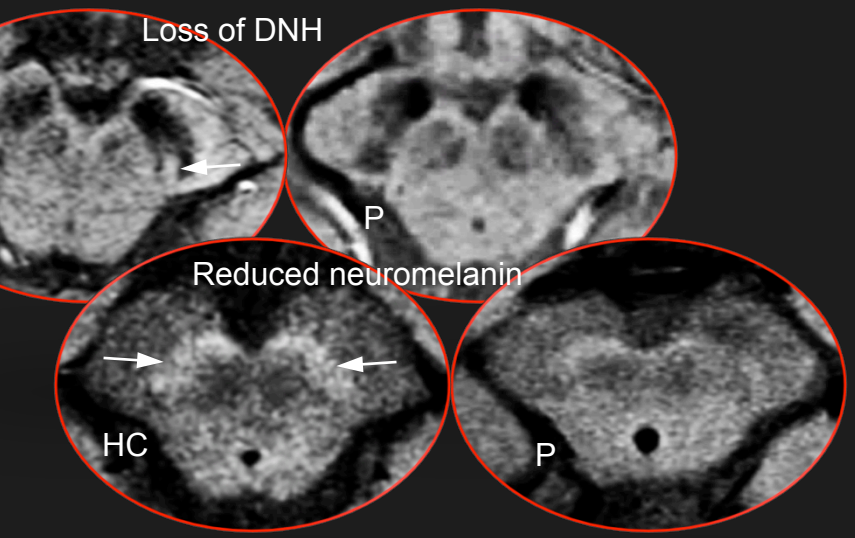

Parkinsonism

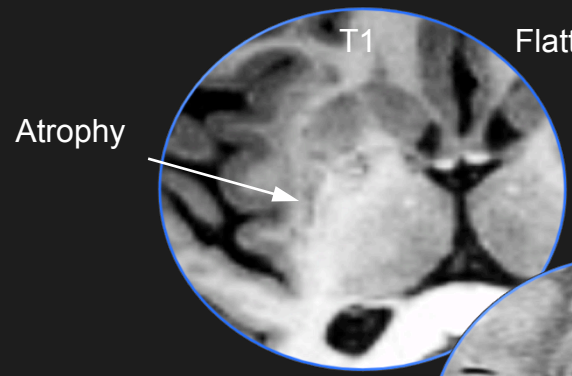

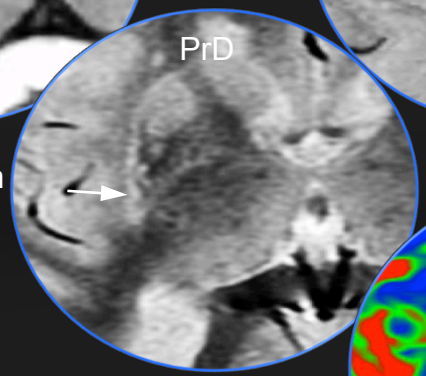

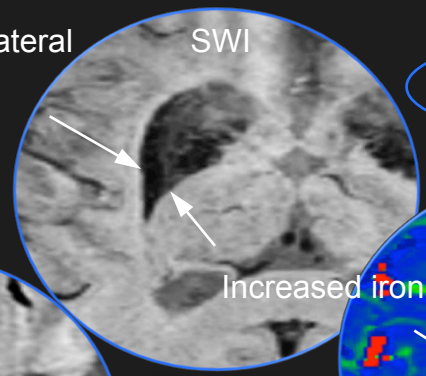

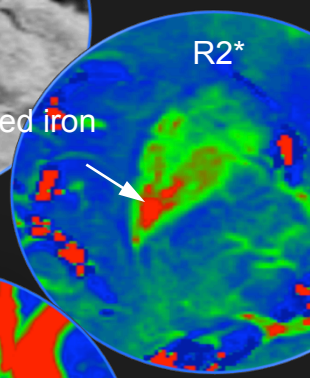

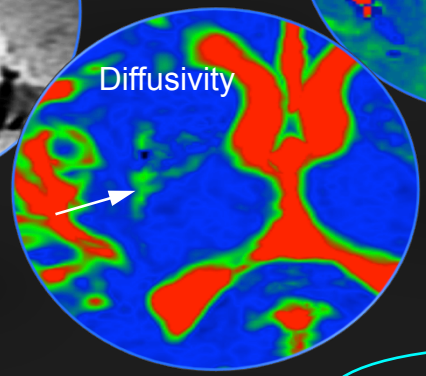

MSA-P

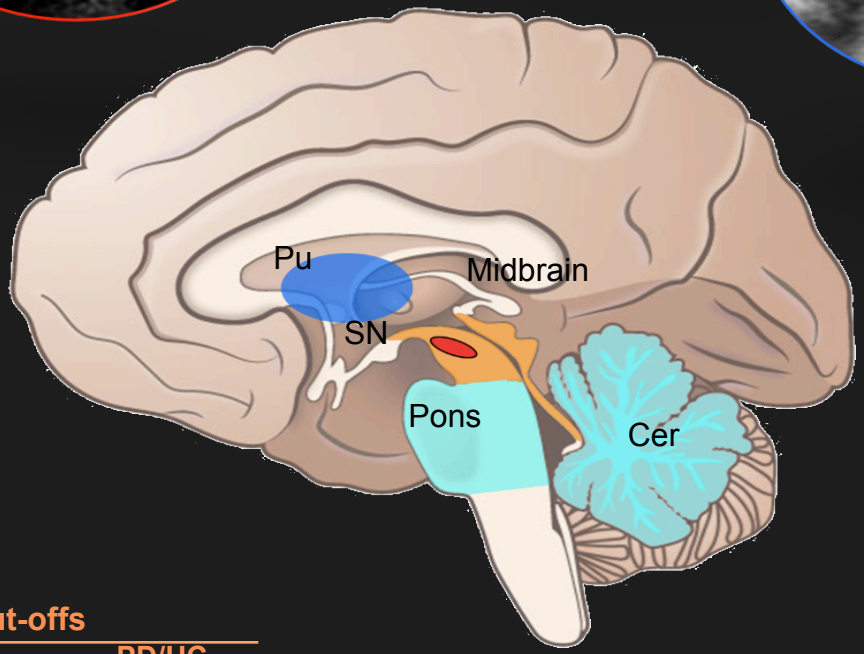

PSP

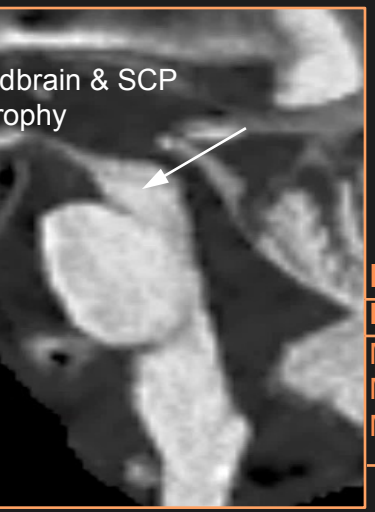

Diagnostic cut-offs

PSP-RS vs.	PD/HC
Midbrain area (mm2)	< 120
M/P	< 0.20
MRPI	> 13.6

MSA-C

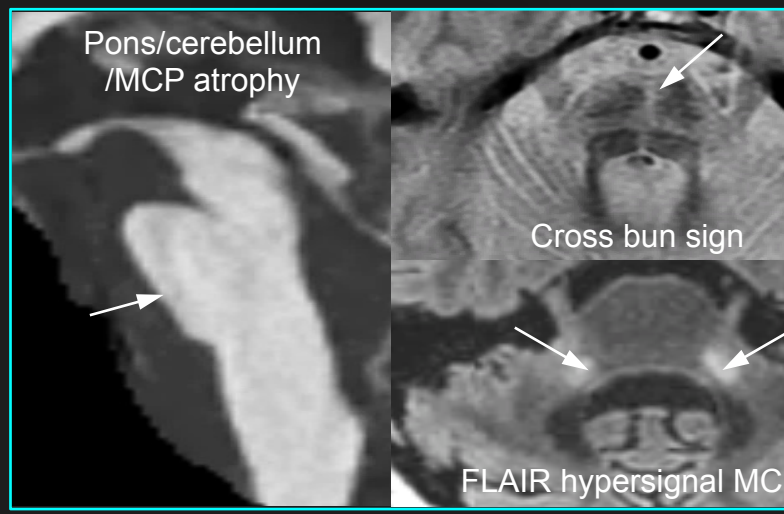

Take home messages

- **Reduced NM signal and loss of DNH in the substantia nigra**
  - Are signs of neurodegenerative parkinsonism
  - Distinguishes parkinsonism from essential tremor and non-degenerative parkinsonism
  - Do not distinguish parkinsonian subtypes

- **Atypical Parkinsonism**
  - PSP: Midbrain atrophy, hummingbird sign
  - MSAc: Pons, cerebellum and peduncles atrophy, hot cross bun sign
  - MSAp: Posterior putamen, iron deposition, atrophy, high T2 rim, increased ADC

- **MRI effectively distinguishes PD, PSP and MSA in clinical practice**

- **Effective automated approaches may be useful in the future**

- **More studies are needed to determine the role of MRI**
  - In the early and preclinical stages
  - In PSP variants

cknowledgements

CM – Paris Brain Institute
Movement Disorders Clinic
Department of Neuroradiology
Paris, Hôpital de la Salpêtrière

sabelle Arnulf
Emma Biondetti
Lydia Chougar
Rahul Gaurav
David Grabli
Smaranda Leu-Semenesc
Nadya Pyatigorskaya
Marie Vidailhet

Avicenne Hospital, Neurology Department, Bobigny, France

Bertrand Degos
Alice Faucher

International Parkinson Movement Disorders Society-Neuroimaging Study Group
Cecilia Peralta, Antonio P. Strafella, Thilo v
Eimeren, Roberto Ceravolo, Klaus Seppi,
Valtteri Kaasinen, Julieta E. Arena